

## Perforated Duplex Vermiform Appendix: A Rare Emergency

**Satyendra K Tiwary, Shivanshu Singh, Puneet Kumar, Ajay Kumar Khanna**  
Department of General Surgery, Institute of Medical Sciences, Banaras Hindu University,  
Varanasi 221005, India

This is an Open Access article distributed under the terms of the Creative Commons Attribution License (<http://creativecommons.org/licenses/by/3.0>), which permits unrestricted use, distribution, and reproduction in any medium, provided the original work is properly cited.

### Abstract

**Background:** Duplex appendix is a rare congenital problem which may remain asymptomatic but sometimes presents as acute abdomen. Per operative identification of both the appendices is essential, otherwise the unattended appendix may lead to serious life threatening and medico legal consequences in the future.

**Case report:** We report a case of 26 years male who presented to the emergency with acute pain abdomen for 10 days and high grade fever. On exploration, two inflamed vermiform appendices were identified, one of them having perforation and both were attached to a single caecum. Appendicectomy of both the appendices was done. Postoperative period remained uneventful.

**Conclusions:** Preoperative diagnosis of duplex appendix is difficult. Diagnostic laparoscopy is used as a minimally invasive tool for diagnosis in cases of previous appendicectomy.

**Keywords:** Duplex appendix, Appendicitis, Laparotomy, Acute abdomen

### Background

Duplication of appendix is a rare condition. Collins (1955) reported duplication in only 2 of the 50000 appendix specimens studied [1]. Though rare, their intra-operative identification and management prevents further attack of appendicitis and related life-threatening complications. We hereby report a case of perforated duplex vermiform appendix who presented as acute abdomen.

### Case Presentation

A 25 years old male presented to the emergency with history of pain right lower

abdomen for 10 days and high grade fever for 3 days. Pain was non colicky, progressively increasing in severity, especially in the last three days. It was partially relieved on taking analgesics with no migration, radiation or postural variation. Fever was persistent for 3 days, was associated with chills and was partially relieved on taking medications. He had not passed stools for the last two days. There was no h/o past surgical intervention or medical co-morbidities.

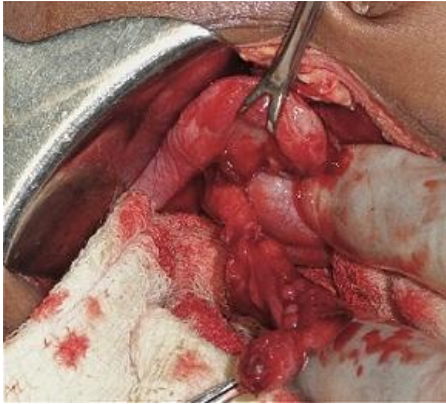
On examination, patient had fever of 101 °F, tachycardia and tachypnoea. Abdominal examination revealed tenderness with localized guarding in the right iliac fossa. There was no palpable organomegaly or lump abdomen. Shifting dullness was absent and bowel sounds were sluggish. Digital rectal examination revealed tenderness in the right lateral rectal wall.

#### Address for correspondence and reprint requests to:

Dr. Ajay Kumar Khanna, Professor, Department of General Surgery, Institute of Medical Sciences, Banaras Hindu University, Varanasi, Uttar Pradesh, India – 221005. Email: [akhannabhu@gmail.com](mailto:akhannabhu@gmail.com)

© 2016 Tiwary SK et al. Licensee Narain Publishers Pvt. Ltd.

Submitted: Saturday, November 28, 2015; Accepted: Friday, August 19, 2016; Published Saturday, August 20, 2016

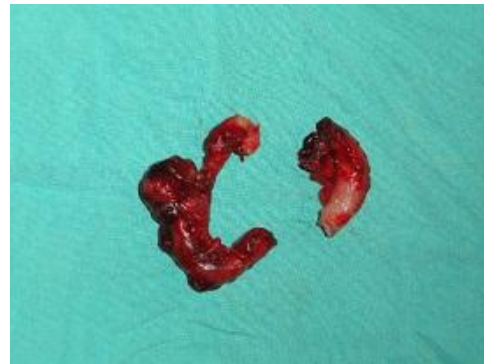

**Figure1: Intraoperative photograph of duplex appendix**

On radiological examination, X-ray chest and abdomen were unremarkable. Haemoglobin was 11.4 gm%, TLC was 15200 cells/mm<sup>3</sup>. Renal and liver function tests were normal. Ultrasound abdomen revealed a large heteroechoic collection in the lower abdomen suggestive of pyoperitoneum with mild hydronephrosis right side. In view of the above findings, decision for laparotomy was taken.

The patient underwent exploratory laparotomy. Nearly 500 ml purulent collection was present in the peritoneal cavity. Omentum was found adhered to the caecum and the terminal ileum. Two appendices were indentified, each attached separately to a single caecum. One was 8 cm long, 2.5 cm wide, inflamed, pelvic in position and perforated at the tip arising from the confluence of the taenia and adhered with surrounding structures. The other one was 5 cm long, 2 cm wide, preileal in position, inflamed and arising separately from the anterior taenia coli about 3-4 cm away from the normal one (Figure 1). Both of them had their separate mesoappendix. The base of each appendix was ligated separately and appendicectomy with peritoneal lavage was performed. The patient had good postoperative recovery.

Histopathological examination confirmed appendicular micro-architechture in both the



**Figure 2: Specimens of the two appendices**

specimens (Figure 2) with lymphoid follicles and dense mixed transmural inflammation reaching up to serosa with no evidence of granuloma or malignancy seen.

### Discussion

Duplex appendix vermiformis is a rare condition with a reported incidence of 0.004% to 0.009% of appendicectomy [2]. Most of the cases are identified at the time of post-mortem examination or laparotomy for other indications [3]. Classification of duplex appendix was first proposed by Cave in 1936, later modified by Wallbridge in 1963 and Biermann in 1993 [4-6].

At present further types of appendix duplication have also been added up [7, 8] (table 1).

Our case was type B2 as one appendix was at its normal location while the other was arising from the taenia. Inflammation usually occurs in both the appendices but sometimes, only one appendix may be involved [9, 10]. Our case had inflammation of both the appendices. Type B2 duplication is supposed to be developing from the persistence of the transient caecal protuberance of the sixth week embryo [10].

Preoperative diagnosis of duplex appendix is difficult. Diagnostic laparoscopy is used as a minimally invasive tool for diagnosis in cases of previous appendicectomy [11]. Peddu and

**TABLE 1. Classification of Duplex Appendix**

Type A	Single caecum with various degrees of incomplete duplication.
Type B1 (bird type)	Two appendices symmetrically placed on either side of the ileocecal valve
Type B2 (taenia coli type)	One appendix arises from the caecum at the usual site, and the second appendix branches from the caecum along the lines of the taenia at various distances from the first.
Type B3	One appendix arises from the usual site, and the second appendix arises from the hepatic flexure
Type B4	One appendix arises from the usual site, and the second appendix arises from the splenic flexure
Type C	Double caecum, each with an appendix
Horseshoe appendix	One appendix has two openings into a common cecum
Triple appendix	One appendix arises from the caecum at the usual site, and two additional appendices arise from the colon

Siddhu in 2004 described the appearance of type B1 duplication on barium enema showing two appendices arising from the posteromedial aspect of the caecum, in close relation to the ileocaecal valve [12]. Duplex appendix must be differentiated from caecal diverticulum. The latter is usually situated on the inner aspect of the ileocaecal angle and has no lymphoid tissue on histological examination [5]. Use of CT scan is uncommon. The differential diagnosis for a case presenting with right iliac fossa pain includes appendicitis, congenital caecal diverticulum, acute mesenteric adenitis, intussusception, inflammatory bowel disease, stump appendicitis, genitourinary problems, or appendicitis in a duplex appendix in a case giving history of previous appendectomy [10].

Misdiagnosis and mismanagement leads to serious life threatening complications like recurrent appendicitis, appendicular perforation, peritonitis and medico-legal consequences. Maizels reported a case wherein a child underwent two appendectomies in a period of 5 months [13]. The diagnosis of duplex appendix warrants the search for other intestinal anomalies like duplication of colon, gastroschisis, genitourinary or vertebral malformations [10, 14, and 15].

### Conclusions

Duplex appendix is a rare congenital problem which may remain asymptomatic but sometimes presents as acute abdomen. Misdiagnosis and mismanagement leads to serious life threatening complications like recurrent appendicitis, appendicular perforation, peritonitis and medico-legal consequences.

### Learning points

1. Appendicular duplication is a rare but important congenital anomaly.
2. It is essential for the surgeons to perform a detailed inspection of the caecum to rule out congenital anomalies of the appendix during appendectomies.
3. A missed duplex appendix may present later with serious life threatening and medico legal consequences.
4. Presence of duplex appendix calls for the search of other congenital anomalies

### Authors' contribution

**SKT** searched the literature and drafted the manuscript.

**SS** designed the study and drafted the manuscript.

**PK** critically reviewed the manuscript and finally drafted manuscript.

**AKK** critically reviewed and finally drafted the manuscript.

**SKT,SS,PK,AKK** approved final version of the manuscript.

### Conflict of Interests

The authors declare that there are no conflicts of interests.

### Ethical considerations

Written informed consent was obtained from the patient for publication of this case report. A copy of the consent is available with the authors.

### Funding


None declared

### References

- Collins DC. A study of 50,000 specimens of human vermiform appendix. Surg Gynecol Obstet 1955; 101:437-45.[PubMed]
- Varshney M, Shahid M, Maheshwari V, Mubeen A, Gaur K. Duplication of appendix: an accidental finding. BMJ Case Reports 2011; doi:10.1136/bcr.01.2011.3679.[PubMed]
- Khanna AK. Appendix vermiformis duplex. Postgraduate Medical Journal 1983; 59:69-70.[PubMed]
- Cave AJE. Appendix vermiformis duplex. J Anat. 1936; 70:283-92.[PubMed]
- Wallbridge PH. Double appendix. Br J Surg. 1963; 50:346-7.[PubMed]
- Biermann R. Appendix duplex. Eine Pathologische Raritat 1993;64:1059-61[PubMed]
- Tinckler LF. Triple appendix vermiformis: a unique case. Br J Surg. 1968; 55:79-81. [PubMed]
- Mesko TW, Lugo R, Breitholtz T. Horseshoe anomaly of the appendix: a previously undescribed entity. Surgery. 1989; 106:563-6. [PubMed]
- Chew DK, Borromeo JR, Gabriel YA, Holgersen LO. Duplication of the vermiform appendix. J Pediatr Surg. 2000; 35:617-8.[PubMed]
- Travis JR, Weppner JL, Paugh JC: Duplex vermiform appendix: case report of a ruptured second appendix. J Pediatr Surg 2008, 43:1726-8 [PubMed]
- Canbay E, Akman E. Appendix perforation in appendix duplication in a man: a case report. J Med Case Reports. 2011; 5: 162.[PubMed]
- Peddu P, Sidhu PS. Appearance of a Type B duplex appendix on barium enema. The British Journal of Radiology 2004; 77 :248-9.[PubMed]
- Maizels G. Duplication of the vermiform appendix. S Afr Med J 1966;40:1123.[PubMed]
- Kabay S, Yucel M, Yaylak F et al. Combined duplication of the colon and vermiform appendix in an adult patient. World J Gastroenterol 2008 ; 14: 641-3.[PubMed]
- Gilchrist BF, Scriven R, Nguyen V, et al. Duplication of the vermiform appendix in gastroschisis. J Am Coll Surg 1999; 189:426. [PubMed]



**World Journal of Medical and  
Surgical Case Reports**



Published by **Narain Publishers Pvt. Ltd. (NPPL)**  
The **Open Access** publishers of **peer reviewed** journals. All articles are immediately published online on acceptance. All articles published by **NPPL** are available **free** online. Authors retain the copyright under the Creative commons attribution license.  
The license permits unrestricted use, distribution, and reproduction in any medium, provided the original work is properly cited