

## An ambiguous type of primary internal hernia as the cause of small bowel obstruction a case report

**Majd Alobied, Ahmad Al-haj, Mohammad Tareq Kattan,**

<sup>1</sup>MD, PHD, Department of surgery, Aleppo University, Syria.

<sup>2</sup>Assistant professor, Department of surgery, Aleppo university hospital, Syria.

<sup>3</sup>MD, Aleppo University, Syria.

This is an Open Access article distributed under the terms of the Creative Commons Attribution License (<http://creativecommons.org/licenses/by/4.0>), which permits unrestricted use, distribution, and reproduction in any medium, provided the original work is properly cited.

### Abstract

**Introduction:** Internal hernia is an important rare cause of small bowel obstruction especially, in a virgin abdomen, without previous abdominal surgery.

Clinical symptoms and signs are nonspecific, and preoperative diagnosis is rare even with modern diagnostic methods.

**Clinical presentation:** Herein, we report a case of a 60-year-old man who complained of a severe abdominal pain, nausea and obstipation. His clinical examination revealed distended abdomen and high-pitched bowel sounds indicating bowel obstruction. After resuscitation of the patient, laparotomy was done to discover an internal hernia through filmy adhesions in peri-hepatic region, as a new type of primary internal hernia. Next, reduction was done and the patient was discharged after 3 days to be on follow up.

**Conclusion:** Although there are several common causes of intestinal obstruction (post-surgery adhesions, inguinal hernia, malignancies etc.), other rare causes should be suspected.

**Keywords:** filmy adhesions, virgin abdomen, obstipation, abdomen distended.

### Introduction

Internal hernias are either congenital or acquired, the latter constituting the majority. Important causes of acquired internal herniation in adults are previous abdominal surgery (mainly liver transplantation and bariatric procedures like gastric bypass), trauma, peritoneal inflammation, or ischemic changes. Primary or congenital internal hernias in adults are extremely rare.[1]

Internal hernias are more common in the pediatric population and seldom seen

among adults. In children, internal hernias are usually congenital whereas in adults they are usually iatrogenic or caused by trauma.[2]

We describe here a case of a rare type of primary internal hernia presenting as acute intestinal obstruction in a 60-year-old Syrian male.

### Case report

A 60-year-old male was admitted to the emergency department with a severe colicky abdominal pain that had started four hours ago. The pain was dull, poorly localized and accompanied by nausea, vomiting and obstipation.

[Address for correspondence and reprint requests to:](#)

MajdAlobied, Aleppo, Syria E-mail:

majdalobied@yahoo.com ©2020

Tel no: 963 999 441 708 Alobied M *et al.* Licensee Narain Publishers Pvt. Ltd. (NPPL)

Submitted Tuesday, February 18, 2020 Accepted:

Thursday, May 28, 2020 Published: Friday, May 29, 2020

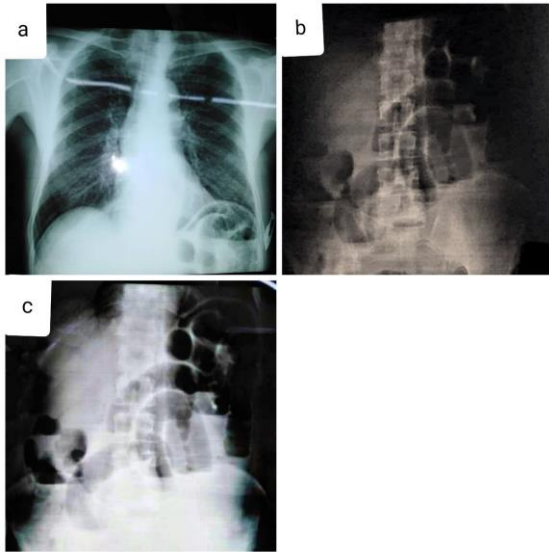


Figure 1: a- chest x-ray shows air-fluid levels in the stomach pouch, b-cupward abdominal x-ray shows distended bowel loops with air-fluid levels

There was no history of any illness, past surgical intervention, or trauma; however, the patient was a smoker. Physical examination showed normal vital signs, abdominal distention, mild tenderness to palpation, and hyperactive bowel sounds on auscultation. No hernia was discovered and no blood was detected on the digital rectal examination.

Routine blood tests were within normal limit. Abdominal x-ray in the upright position showed dilated small intestinal loops, multiple air-fluid levels; suggesting intestinal obstruction. Figure (1).

Resuscitation was initiated and a nasopharyngeal tube was inserted, Unfortunately, CT was unavailable at that time because of breaking down. we proceeded to do an exploratory laparotomy after 24 hours, because the patient was reluctant to surgery initially, which revealed an ileum loop incarcerated in to a defect in abnormal filmy adhesions in peri-hepatic region. The abnormal adhesions were between the anterior surface of the right lobe of the liver and the diaphragm obliterating the sub phrenic space. (Figure 2, Figure 3).

The hernia was reduced, the adhesions were taken down, and The loop was found to be viable after reduction for which resection was not required. After that, the patient was discharged on day 3 with uneventful recovery. He is now on follow-up monthly with no problems.

## Discussion

Meyers *et al.*, have defined an internal hernia as a protrusion of abdominal viscera through an opening within the confines of the peritoneal cavity, although not all internal hernias are strictly intra-peritoneal. Orifices of internal hernias can be congenital or acquired. Congenital orifices include a normal foramen or unusual peritoneal fossae or recesses related to failure of peritoneal fusion, whereas acquired orifices result from trauma, inflammation, or previous surgery. In most

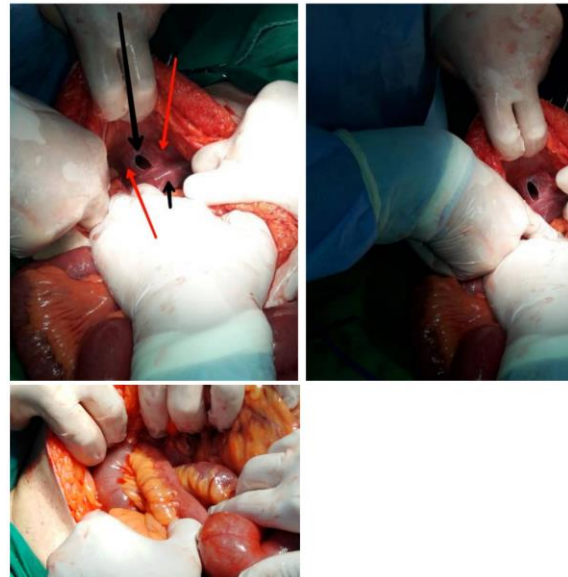
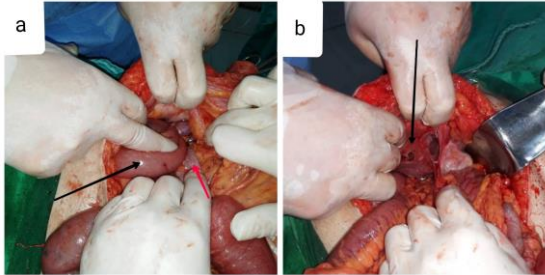


Figure 2: Long black arrow: the defect in the adhesion, short one: liver edge, red arrows refer to the filmy adhesions

cases, the herniated viscera are small bowel loops.

Clinical signs and symptoms of internal hernia are nonspecific and overlap with those of other pathologic conditions in the abdomen.



Fig(3)a:the incarcerated loop, the black arrow shows the distended part , the red arrow shows the collapsed one, b black arrow shows the filmy adhesions during resection

The most common clinical symptoms are nausea, vomiting, abdominal pain, and abdominal distention [3].

This non-specific clinical presentation often leads to a delay in diagnosis, in most cases made at the time of laparotomy, and consequently in proper treatment, carrying risk of serious complications; therefore, when the possibility of internal hernia is considered, a rapid imaging evaluation is necessary to aid an early diagnosis and a prompt intervention [4].

### Conclusions

Even without risk factors such as previous abdominal surgery, trauma or peritoneal inflammation, the possibility of small bowel obstruction secondary to internal hernia should be considered [5].

Since our patient lacked the factors mentioned above, this increases the possibility of a congenital abnormality as a pathogenesis of this case.

### Learning points

1-Internal hernia is a rare surgical case.

2-intestinal obstruction symptoms are known but the reasons may be unclear.

3-All surgeons must think about primary internal hernias as important rare causes of bowel obstruction.

### Conflict of interests

All authors declare no conflict of interest in this article.

### Acknowledgements

Not applicable

### Funding

No funding was involved in this study.

### Consent for publication

Written informed consent was obtained from the patient for publication of this case report and accompanying images.

### Authors contributions

Ahmad AL-Haj (AA): did the management.

Majd Alobied(MA):did the management and critical review.

Mohammad Tareq Kattan (MTK): did the collection and review.

### References

- [1]. Kar S, Mohapatra V, Rath PK. A Rare Type of Primary Internal Hernia Causing Small Intestinal Obstruction. *Case Rep Surg*. 2016;2016:3540794. doi:10.1155/2016/3540794 [PubMed] [PMC]
- [2]. Byard RW, Wick R. Congenital mesenteric defects and unexpected death-a rare finding at autopsy. *Pediatr Dev Pathol*. 2008;11(3):245-248. doi:10.2350/07-12-0392.1 [PubMed]
- [3]. Doishita S, Takeshita T, Uchima Y, et al. Internal Hernias in the Era of Multidetector CT: Correlation of Imaging and Surgical Findings. *Radiographics*. 2016;36(1):88-106. doi:10.1148/rg.2016150113 [PubMed]
- [4]. Lanzetta MM, Masserelli A, Addeo G, Cozzi D, Maggialelli N, Danti G, Bartolini L, Pradella S, Giovagnoni A, Miele V. Internal hernias: a difficult diagnostic challenge. Review of CT signs and clinical findings. *Acta Biomed*. 2019

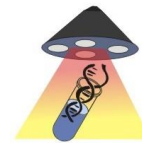
Apr 24; 90(5-S): 20-37. doi:  
10.23750/abm.v90i5-S.8344. PMID:  
31085971; PMCID: PMC6625567. [[PubMed](#)]  
[[PMC](#)]

[5]. Lee SH, Lee SH. Spontaneous transomental  
hernia. Ann Coloproctol. 2016; 32(1):38-41. .  
doi: 10.3393/ac.2016.32.1.38. [[PubMed](#)]  
[[PMC Full Text](#)]



## World Journal of Medical Research

## World Journal of Surgical Research



## World Journal of Surgical, Medical and Radiation Oncology



## World Journal of Medical and Surgical Case Reports

## World Journal of Pathology



Published by **Narain Publishers Pvt. Ltd. (NPPL)**  
The **Open Access** publishers of **peer reviewed** journals. All  
articles are immediately published online on acceptance.  
All articles published by **NPPL** are available **free** online  
Authors retain the copyright under the Creative commons  
attribution license.  
The license permits unrestricted use, distribution, and  
reproduction in any medium, provided the original work is  
properly cited.