

Pleomorphic Sarcoma in Paratesticular Region

Sheela K.M., Lailaraji N., Anitha Asokan C.

Department of Pathology, Government Medical College, Thiruvananthapuram, Kerala, India

This is an Open Access article distributed under the terms of the Creative Commons Attribution License (<http://creativecommons.org/licenses/by/4.0>), which permits unrestricted use, distribution, and reproduction in any medium, provided the original work is properly cited.

Abstract

Background: Primary tumors of the paratesticular region are rare, with paratesticular sarcomas constituting a major proportion of these tumors, particularly in the elderly. The paratesticular region consists of mesothelial, various epithelial and mesenchymal cells and may therefore give rise to a number of tumors with various behaviors.

Case presentation: We present a case of a 63-year-old male with a paratesticular mass clinically diagnosed as Epididymal cyst. Histopathological examination finally led to the diagnosis of undifferentiated pleomorphic sarcoma.

Conclusions: We report this case due to its rarity and due to the limited nature of data and definitional variations.

Key-words: Pleomorphic sarcoma, sarcoma, paratestis

Introduction

As the paratesticular region contains various structures, including the epididymis, spermatic cord, tunica vaginalis and strong fat ligament muscle supporting tissues, it may give rise to a number of tumor types with various behaviors [1]. Paratesticular region has a complex anatomy and contains epididymal, testicular appendages, spermatic cord, testicular tunics and vestigial remnants. Neoplasia originating from this region comprises of a heterogeneous group of tumors [2].

The majority of the masses within the scrotum in adults are of testicular origin. Paratesticular masses account for 2-3% and sarcomas account for ~30% of all scrotal masses [3]. The most common type of sarcoma is liposarcoma,

followed by leiomyosarcoma (LMS), rhabdomyosarcoma (RMS), undifferentiated pleomorphic sarcoma and fibrosarcoma [4]. To the best of our knowledge, only one instance of low grade fibromyxoid sarcoma in a paratesticular location has been previously reported. Pleomorphic sarcoma, not otherwise specified/undifferentiated pleomorphic sarcoma (UPS), earlier known as malignant fibrous histiocytoma (MFH), is a common soft-tissue tumor in adults. The most frequent primary sites include the lower (49%) and upper (19%) extremities, and the retroperitoneum and abdomen (16%). However, paratesticular/scrotal UPS is a rare entity. It constitutes approximately 13% of all malignant tumors in the paratesticular region. More than 75% of the tumors in this region arise from the spermatic cord and are mostly benign [5]. We report a case of UPS of the scrotum in a 63-year-old man. The prognosis is often poor, as recurrence and metastasis are common, and the mechanism and outcome of regional lymph node resection, radiotherapy and chemotherapy is unclear. We report this case

Address for correspondence and reprint requests to:

Sheela KM. Department of Pathology, Government Medical College, Thiruvananthapuram, Kerala, India
Email sheelakm51@gmail.com

© 2017 Sheela KM et al. Licensee Narain Publishers Pvt. Ltd.
Submitted Wednesday, March 22, 2017; Accepted: Tuesday, May 16, 2017 Published Saturday, June 17, 2017

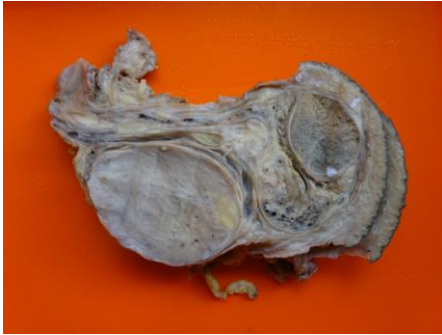

Figure 1.Gross photograph showing an encapsulated mass in the paratesticular region, which is greywhite , firm with yellowish areas.(original image)

due to its rarity and due to the limited nature of data and definitional variations.

Case Presentation

A 63 year old male presented with a gradually increasing left scrotal mass since 10 months. The swelling was associated with pain. The patient did not give any history of loss of weight or appetite. On examination, a firm, nodular, mass was found in the scrotum with normal appearing scrotal skin. Inguinal lymph nodes were not palpable. Lab findings showed a haemoglobin of 12.1gm/dl, white blood cell count of 9,300/mm³ with predominantly neutrophils. ESR was 45 mm/hr, Platelet count - 2.06 lakhs. All other investigations were within normal limits.

With a clinical diagnosis of Epididymal cyst, scrotal exploration was done and biopsy specimen sent for histopathological examination.

On gross examination solid grey white, soft tissue were found. Histopathological examination revealed a tumor arranged in sheets (Figure 1). Tumor cells showed marked nuclear pleomorphism with a round to oval to spindled nuclei, with moderate amount of eosinophilic cytoplasm, pleomorphic nuclei and vesicular chromatin. Brisk mitotic activity (with more than 10 mitoses/10 hpf) was seen. A diagnosis of Pleomorphic sarcoma (FNCLCC

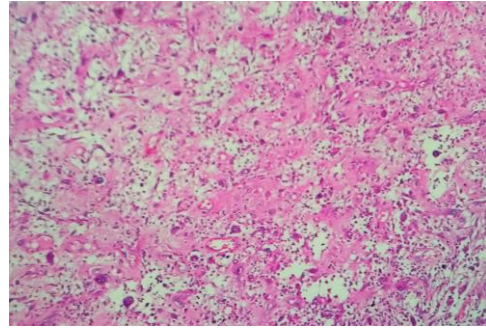


Figure 2 -neoplasm composed of cells arranged haphazardously (H&E 10x)

grading system) was thus made and immunohistochemistry was performed. Immunohistochemical examination showed strong positivity for vimentin in tumor cells. Tumor cells were negative for smooth muscle actin, desmin, cytokeratin, CD 34, and S100 (Figure 5). Thus, a final diagnosis of undifferentiated high-grade pleomorphic sarcoma was rendered.

An ultrasonography of scrotum was ordered that revealed thickened right spermatic cord with three hypoechoic well encapsulated collections with low level internal echoes within. The patient then underwent a radical orchiectomy.

The resected specimen showed an encapsulated mass in the paratesticular region. Mass measured 8x5.5x4 cm and cut surface is solid, grey white, fleshy with yellowish areas and tiny cystic spaces. Adjacent testis showed normal morphology.

Histologically, sections showed a neoplasm composed of cells arranged haphazardly (Figure 2). Cells showed marked pleomorphism with high N/C ratio, pleomorphic vesicular nucleus with clumped chromatin. Few spindly and stellate cells seen. Many binucleate and multinucleate cells with numerous mitotic figures (0-2/ HPF) noted (Figure 3, 4). Tumour cells showed diffuse and strong positivity for Vimentin (Figure 5) and were negative for smooth muscle actin (SMA), S100, desmin, and

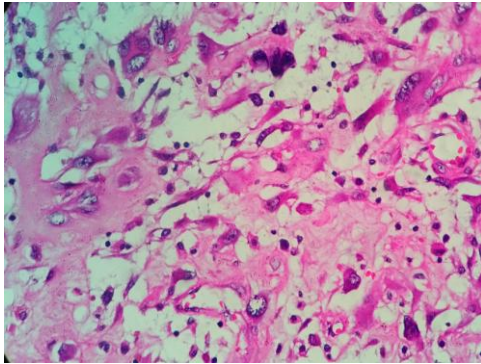


Figure 3 Cells showed marked pleomorphism with high N/C ratio, pleomorphic vesicular nucleus with clumped chromatin (H&E 40x)

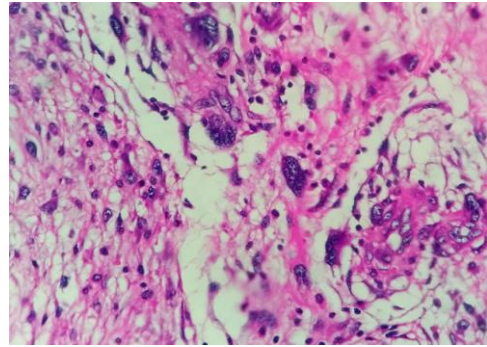


Figure 4 Many binucleate and multinucleate cells with numerous mitotic figures ((H&E 40x)

CD34. Patient was referred for a postoperative chemoradiation.

Discussion

Pleomorphic sarcoma, not otherwise specified/UPS is one of the most common sarcomas occurring between the ages of 50 and 70 years. The sites of predilection include the lower extremities and retroperitoneum. In paratesticular region, Liposarcoma and LMS are the most common sarcomas [6]. RMS is more frequent in younger patients [7]. UPS of the spermatic cord and the paratesticular area is rare. Preoperative diagnosis of spermatic cord MFH/UPS is challenging, as the origin and nature of an inguinal mass cannot be precisely determined by clinical presentation and physical examination. Most tumors occur as a painless, slowly growing, localized solitary mass, although some cases may present as multiple satellite tumor nodules, with the involvement of scrotal skin in rare cases [8]. The tumour is often misdiagnosed as a benign condition such as a hernia, spermatocele or hydrocoele.

Important differential diagnoses need to be considered at this site before reaching a diagnosis of UPS. Unlike testicular masses, paratesticular masses are usually benign. They may be either solid or cystic. Cystic masses include hydrocoele, epididymal cyst, and varicocele. The most common cause of

abscess in the scrotal region is epididymitis or epididymo-orchitis. Most of the solid masses are also benign, with the prevalence of malignancy being only 3% [9]. The most common paratesticular neoplasms are spermatic cord lipomas and adenomatoid tumors of the epididymis. Malignant tumors of the paratesticular region can have mesenchymal, epithelial, germ cell, mesothelial, and lymphoid origin. Spermatic cord is the most common site of genitourinary sarcomas, which include leiomyosarcoma (32%), rhabdomyosarcoma (24%), liposarcoma (20%), pleomorphic sarcoma, not otherwise specified (13%) [10].

Ultrasonography is the primary modality for imaging scrotal lesions. It provides excellent spatial resolution and has been shown to be nearly 100% sensitive in distinguishing testicular and paratesticular pathologies. Magnetic resonance imaging further helps in the establishment of a more specific diagnosis [11].

Morphological variants of spermatic cord MFH/UPS include the pleomorphic (83%), giant-cell (9%) and inflammatory (6%) and, very rarely, myxoid subtypes [12]. The French Federation of Cancer Centers Sarcoma Group grading system is used for the grading of sarcomas [13]. In this system, the grade is obtained by scoring the degree of tumour differentiation, mitotic count, and the amount of tumour necrosis. Differentiation of UPS from

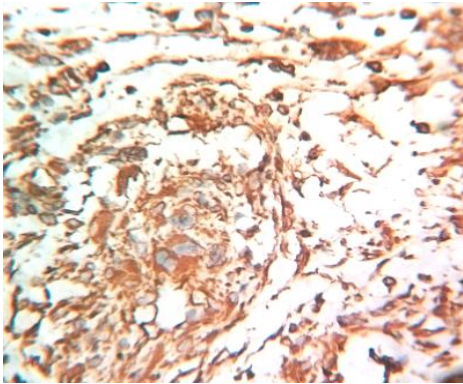


Figure 5 : Tumor cells showed diffuse and strong positivity for Vimentin (40x)

other malignant tumours that exhibit a comparable degree of cellular pleomorphism is of particular importance. The differential diagnosis thus includes anaplastic carcinoma, malignant melanoma, and pleomorphic forms of liposarcoma, leiomyosarcoma, and rhabdomyosarcoma. Careful examination of the histopathological features and immunohistochemical profile helps in reaching a definitive diagnosis

Treatment of paratesticular sarcomas is primarily surgical (inguinal orchiectomy with high ligation of the spermatic cord). After orchiectomy wide en bloc resection of the adjacent soft tissue has been used for spermatic MFH/UPS. Ipsilateral pelvic lymphnode dissection is advised. Decrease in local recurrence rate has been reported with adjuvant radiotherapy and/or after orchiectomy [14]. In our case a radical orchiectomy was done followed by chemoradiation. The prognosis is often poor as recurrence and metastasis are common. Prognosis of UPS depends on tumour size, grade, stage, and histology and lymphnode involvement.

Conclusions

Paratesticular region consists of complex structures that can develop various neoplastic formations and patterns. Sarcomas comprise a significant part of paratesticular masses and may exhibit an aggressive clinical course. In

older patients, paratesticular sarcomas must be considered for the differential diagnosis of scrotal masses, which do not exhibit a clear association with the testes. Furthermore, clinicians and patients must be informed about the high probability of local recurrence and distant metastasis in paratesticular sarcomas.

Key Message

- Pleomorphic sarcoma, not otherwise specified/undifferentiated pleomorphic sarcoma (UPS) is one of the most common sarcomas occurring between the ages of 50 and 70 years.
- Defining the association between the paratesticular mass and the testicle, and differentiation between benign and malignant masses using radiology is challenging, therefore the mass is usually considered to be malignant and radical orchiectomy with high ligation is performed.

Authors contribution

SKM: Histopathologic reporting, concept, preparation and review of manuscript.

LRN: Histopathologic reporting, design and draft of manuscript

AAC: Review and editing of manuscript

Conflict of Interest

The authors declare that there are no conflicts of interests

Ethical Consideration

Written informed consent was taken from the patient for publication of this case report. The copy of the consent is available with the authors.

Funding

None

References

1. Lioe TF, Biggart J D: Tumours of Spermatic Cord and Paratesticular Tissue – a clinicopathol study. *Br J Urol* 1993; 71:600-606. [[PubMed](#)]
2. Khoubehi B, Mishra V, Ali M, Motiwala H, Karim O. Adult Paratesticular Tumours. *BJU Int* 2002; 90: 707- 15. Pmid12410753 [[Free full text](#)]
3. Varzaneh FE, Verghese M, Shmookler BM: Paratesticular leiomyosarcoma in an elderly man. *Urology* 60: 1112, 2002. [[PubMed](#)]
4. Demir A, Onol FF, Türkeri L. Paratesticular pleomorphic rhabdomyosarcoma in an adult. *Int Urol Nephrol.* 2004; 36(4): 577-8.. [[PubMed](#)]
5. Weiss SW, Goldblum JR, editors. Malignant fibrous histiocytoma (pleomorphic undifferentiated sarcoma). In: Enzinger and Weiss's Soft Tissue Tumours. 5th ed. London: Mosby; 2008. p. 1161-82.
6. Woodward PJ, Schwab CM, Sesterhenn IA. From the archives of the AFIP: Extratesticular scrotal masses: Radiologic-pathologic correlation. *Radiographics* 2003; 23: 215-40. [[PubMed](#)]
7. Soosay GN, Parkinson MC, Paradinas J and Fisher C: Paratesticular sarcomas revisited: a review of cases in the British Testicular Tumour Panel and Registry. *Br J Urol* 1996; 77: 143-146. [[PubMed](#)]
8. Galosi AB, Scarpelli M, Mazzucchelli R, Lopez-Beltran A, Giustini L, Cheng L, *et al.* Adult primary paratesticular mesenchymal tumors with emphasis on a case presentation and discussion of spermatic cord leiomyosarcoma. *Diagn Pathol* 2014; 9: 90. [[PubMed](#)] [[PMC Full Text](#)]
9. Hansen T, Katenkamp K, Brodhun M, Katenkamp D: Low-grade fibrosarcoma- report on 39 not otherwise specified cases and comparison with defined low-grade fibrosarcoma types. *Histopathology* 2006; 49: 152-160. [[PubMed](#)]
10. Stojadinovic A, Leung DH, Allen P, Lewis JJ, Jaques DP, Brennan MF: Primary adult soft tissue sarcoma: time-dependent influence of prognostic variables. *J ClinOncol* 2002; 20: 4344-4352. [[PubMed](#)]
11. Eble JN, Sauter G, Epstein JI, Sesterhenn IA (Eds.): World Health Organization Classification of Tumours. Pathology and Genetics of Tumours of the Urinary System and Male Genital Organs. IARC Press: Lyon 2004. ISBN 92-832-2412-4.
12. Fletcher CDM, Bridge JA, Hogendoorn PCW, Mertens F (eds): WHO Classification of Tumours of Soft Tissue and Bone. Vol 5. 4th edition. IARC Press, Lyon, 2013.
13. Weiss SW, Goldblum JR (eds). Enzinger and Weiss, Soft tissue Tumour 5th edition London Mosby 2008:1161-82. ISBN 13: 9780323046282
14. Küçük Ü, Bayol Ü, Pala EE, Akman Ö, Divrik RT. Paratesticular sarcomas: our case series. *Turk J Urol.* 2013 Jun;39(2):84-9. doi: 10.5152/tud.2013.017. [[PubMed](#)] [[PMC Full Text](#)]

World Journal of Pathology



Published by **Narain Publishers Pvt. Ltd. (NPPL)**

The **Open Access** publishers of **peer reviewed** journals. All articles are immediately published online on acceptance.

All articles published by NPPL are available **free** online. Authors retain the copyright under the Creative commons attribution license.

The license permits unrestricted use, distribution, and reproduction in any medium, provided the original work is properly cited.