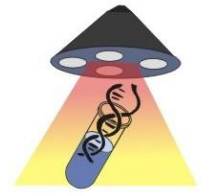


Original Article



Open Access

Submental Intubation in Maxillofacial Trauma Patients: Our Early Experience and Lessons Learned

¹Alok Bharti, ^{2*}Preeti Tiwari, ²Nitesh Mishra

¹Department of Anaesthesiology, Trauma centre, Institute of Medical Sciences, Banaras Hindu University, Varanasi, U.P., India

²Department of Oral and maxillofacial surgery, Faculty of Dental Sciences, Institute of Medical Sciences, Banaras Hindu University, Varanasi, U.P., India

This is an Open Access article distributed under the terms of the Creative Commons Attribution License (<http://creativecommons.org/licenses/by/4.0>), which permits unrestricted use, distribution, and reproduction in any medium, provided the original work is properly cited.

Abstract

Introduction: Trauma is the most common cause of mortality in productive age group across the world children. Complicated maxillofacial injury averting nasal intubation & requiring maxilla mandibular fixation pose a significant challenge with regards to airway access management. The aim of this retrospective analysis of our maxillofacial trauma patient is to present the results of submental intubation and to discuss the indications and result of this procedure.

Patients & Methods: A retrospective study, involving maxillofacial trauma patients of the single maxillofacial unit over a one year period from July 2015 to June 2016. The study included all patients with maxillofacial trauma requiring submental intubation during surgery for maxillofacial trauma. Data were collected from patient's records for age, gender, mode of injury, type of maxillofacial trauma, associated trauma, intraoperative and postoperative complications regarding submental intubation.

Results: A total of 11 patients with maxillofacial trauma admitted during the study period. Submental intubation was successfully performed in 10 patients. Mean disconnection time in other patients was 1.2 ± 0.63 minutes. The mean procedure time was 9.6 ± 3.34 minutes. None of the patients had any motor or sensory disturbance or any complaints regarding salivary gland or duct damage. One patient with diabetes mellitus and uncontrolled blood sugar level developed a post-operative wound infection.

Conclusion: Submental intubation offers an adequate, easy and minimally invasive alternative for polytrauma patients though patients with co-morbidities should be screened to avoid complications.

Key Words: Submental intubation, maxillofacial trauma, wound infection, polytrauma

Address for correspondence and reprint requests to:

Dr Preeti Tiwari, B.D.S, M.D.S, Assistant Professor, Department of Oral and maxillofacial surgery, Faculty of Dental Sciences, Institute of Medical Sciences, Banaras Hindu University, Varanasi, U.P., India, Email address - drtiwaripreeti@gmail.com

©2018 Bharti A et al. Licensee Narain Publishers Pvt. Ltd. (www.npplweb.com)

Submitted: Sunday, October 29, 2017; Accepted: Tuesday, January 23, 2018; Published: Tuesday, January 30, 2018

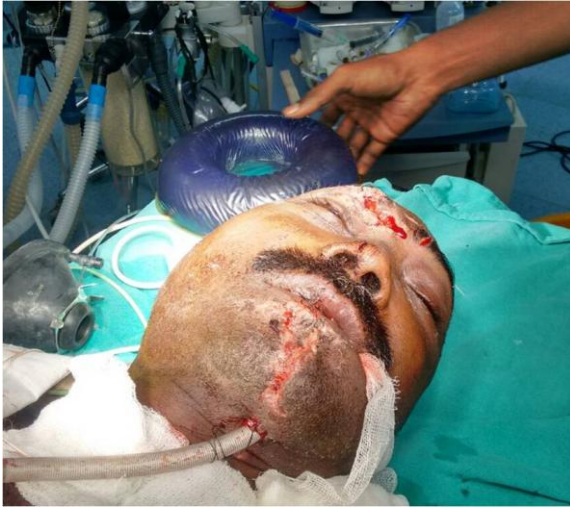

Figure 2: Patient with submental intubation

the wound is closed in layers (Figure 1 and 2).

Results

We scrutinized a total of 11 patients with maxillofacial trauma admitted during the study period (Table 1). Out of the assessed patients, 8 (72.7%) were male patients and 3 (27.2%) were female patients. Patient age ranged from 16-70 year with a mean age of 34.0 ± 17.67 year. Road traffic accident was the most common mode of injury with most patients having complex injuries with a combination of multiple fractures of lower, mid and upper part of the face. Out of 11 patients, 7 (63.6%) had associated injuries. Most common associated injuries were head injuries and abdominal injuries. Submental intubation was successfully performed in 10 patients. One patient, a 70 year male with bilateral wheeze and a long history of smoking developed rapid desaturation immediately after disconnection from ventilator even after adequate pre-oxygenation. His baseline saturation throughout the procedure varied between 85-90%. Mean disconnection time in other patients was 1.2 ± 0.63 minutes. The mean procedure time was 9.6 ± 3.34 minutes. None

of the patients had any motor or sensory disturbance or any complaints regarding salivary gland or duct damage. One patient with diabetes mellitus and uncontrolled blood sugar level developed a post-operative wound infection. The wound was laid open and was allowed to heal by secondary intention. Later the patient developed pus discharge from surgical site which led to the removal of fixating plates. Minimal scarring was observed, without any complaints in all other patients.

Discussion

Since the introduction of submental intubation in 1986 several reports have been published highlighting its utility in different clinical scenarios. This technique paved for a secure airway with an unobstructed intraoral surgical field allowing maxillomandibular fixation with excellent ease. Further, this technique also avoided the drawbacks and complications of nasotracheal intubation and tracheostomy [3]. Excellent results have been reported in the literature with minimal or no motor or sensory deficit, normal healing of the mucosal floor, and preservation of the salivary ducts and saliva production [4-5].

As opposed to the classical description by Hernández Altemir, dissection was performed just over the periosteum and not below it. This avoided an excessive periosteal section of bone fragments that may already have compromised vascularity. This modification has been used by other authors previously [6-7]

Though submental intubation has these advantages, it is not free of adverse effects and complications. The most critical part is the passage of the endotracheal tube through the incision from the interior of mouth to the exterior. It may be difficult to pass the tube through the incision as in one of our cases which developed rapid desaturation. None of

Table 1: Details of patients included in the study

S. No	Age	Gender	Mode of trauma	Fracture	Associated injury	Complications
1.	45	Male	Head on collision from truck	Lefort I, Zygomatic complex fracture, mandible parasymphysis fracture	Head injury, abdominal trauma	None
2.	16	Male	Fall from bike	Maxillary dentoalveolar fracture, mandibular parasymphysis and subcondyle fracture	Head injury	None
3.	35	Male	Assault	Zygomatic complex fracture, nasal bone fracture, maxillary dentoalveolar fracture	None	None
4.	32	Female	Fall from bike	Mandibular dentoalveolar fracture, mandibular symhysis fracture, nasal bone fracture	Musculoskeletal injury	None
5.	29	Male	Car accident	Bimaxillary dentoalveolar fracture, mandibular dentoalveolar fracture, Zygomatic complex fracture, nasal bone fracture	Musculoskeletal injury	None
6.	12	Male	Motor bike accident	Mandibular parasymphysis fracture, Zygomatic complex fracture	None	None
7.	22	Female	Car accident	Lefort II fracture, Mandibular dentoalveolar fracture	Head injury, abdominal trauma	None
8.	19	Male	Auto rickshaw accident	Bimaxillary dentoalveolar fracture mandibular angle fracture	None	None
9.	38	Female	Fall from bike	Lefort I fracture, mandibular parasymphysis fracture	Head injury	None
10	56	Male	Car accident	Nasal bone fracture, lefort I, mandibular dentoalveolar fracture	Head injury	Wound infection with secondary healing
11	70	Male	Fall from stairs	Lefort II fracture, bimaxillary dentoalveolar fracture	None	Failed submental intubation

the other authors have reported this scenario but the difficult passage of tube can be overcome by Green and Moore's modification to the original technique [8]. They used two endotracheal tubes in their technique. They first conventionally secured the airway with an oral tracheal tube. This was followed by passage of another endotracheal tube from exterior to the interior through the submental incision. The original oral tube is then

withdrawn and reinforced tube substituted. The process may be reversed at the end of the procedure. This technique has another advantage that it precludes the removal of the connector which may not be easy in a lot of conditions or is not possible with some manufacturer's design [9]. However, this technique has been criticised as too aggressive for patients and traumatic to the pharyngeal and laryngeal mucosa of patients [10].

Other complications with submental intubations are oral floor abscesses and occurrence of hypertrophic scar formation [2]. But most reports agree that the complications are minimal and that patients are overall very satisfied with the lack of scarring. It has been hypothesized that high pressure due to acute angulation of the tube causes higher chances of complication [3]. In one of our patients, the risk factor was uncontrolled post-operative blood sugars level. In addition to the obvious benefits of submental endotracheal intubation in maxillofacial trauma procedures, elective use of this manoeuvre has been described as efficacious in procedures where an unobstructed oral or nasal cavity is beneficial to the surgeons, such as orthognathic surgery and even transfacial cranial base surgery [11].

Conclusion

In conclusion, the submental intubation offers an adequate, easy and minimally invasive alternative for polytrauma patients though patients with co-morbidities should be screened carefully before endeavoring the procedure to avoid unnecessary complications.

Authors' Contribution

AB: Conception and design, acquisition of data.

PT: Conception and design, acquisition of data analysis and interpretation of data.

NM: Drafted the article and revised the contents.

Conflict of Interests

The authors declare that there are no conflicts of Interests

Ethical Considerations

The study was approved by Institute Ethics

Committee and written informed consent was taken from each participant.

Consent for Publication

Written informed consent was obtained from the study participants for publication of their case records and photographs. The copy is available with authors.

Funding

None Declared

Acknowledgements

None

References

1. Guyer B, Freedman MA, Strobino DM, Sondik EJ: Annual summary of vital statistics: trends in health of Americans during the 20th Century. *Pediatr* 2000, 106(6):1307-1317. [[PubMed](#)]
2. Altemir FH. The submental route for endotracheal intubation: a new technique. *J Maxillofac Surg* 1986; 14: 64-5. [[PubMed](#)]
3. Amin M, Dill-Russell P, Manisali M, Lee R, Sinton I. Facial fractures and submental tracheal intubation. *Anaesthesia*. 2002;57(12):1195-9. [[PubMed](#)] [[Free Full Text](#)]
4. Gordon NC, Tolstunov L. Submental approach to oroendotracheal intubation in patient with midfacial fractures. *Oral Surg Oral Med Oral Pathol Oral Radiol Endod* 1995;79: 269-72. [[PubMed](#)]
5. Chandu A, Smith ACH, Gebert R. Submental intubation: an alternative to short-term tracheostomy. *Anaesth Intensive Care* 2000; 28: 193-5. [[PubMed](#)]

6. Faraj J, AlKhalil M, Darwishb A, Faraj I, El-Zenati H, Altraifi Y, et al. Submandibular intubation; our experience in Qatar and a short review of literature. Egypt J Ear Nose Throat Allied Sci. 2013;14:119-21. [[Free Full Text](#)]
7. Lazaridis N, Zouloumis L, Tilaveridis I, Lazaridou M, Antoniadou K, Dimitrakopoulos I. Retrotuberosity versus submentosubmandibular and median submental intubation: patients with maxillofacial surgery. Oral Surg Oral Med Oral Pathol Oral Radiol. 2012;114 Suppl.5:S209-15. [[PubMed](#)]
8. Green JD, Moore UJ. A modification of sub-mental intubation. Br J Anaesth 1996; 77: 789-91. [[PubMed](#)] [[Free Full Text](#)]
9. Meyer C, Valfrey J, Kjartansdottir T. Indication for and technical refinements of submental intubation in oral and maxillofacial surgery. J Craniomaxillofac Surg. 2003;31(6):383-8. [[PubMed](#)]
10. Lima SM, Asprino L, Moreira RW, de Moraes M. A retrospective analysis of submental intubation in maxillofacial trauma patients. J Oral Maxillofac Surg. 2011;69:2001-5. [[PubMed](#)]
11. Jundt JS, Cattano D, Hagberg CA, Wilson JW. Submental intubation: a literature review. Int J Oral Maxillofac Surg. 2012;41:46-54. [[PubMed](#)]



**World Journal of Medical and
Surgical Case Reports**



**World Journal of
Trauma and Critical Care
Medicine**

World Journal of Pathology



Published by **Narain Publishers Pvt. Ltd. (NPPL)**
The **Open Access** publishers of **peer reviewed** journals. All articles are immediately published online on acceptance. All articles published by **NPPL** are available **free** online. Authors retain the copyright under the Creative Commons attribution license. The license permits unrestricted use, distribution, and reproduction in any medium, provided the original work is properly cited.